

Rat brain and testicular tissue effects of radiofrequency radiation exposure: Histopathological, DNA damage of brain and qRT-PCR analysis

M.C. Yavas^{1*}, A. Kilitci², E. Çelik³, K. Yegin⁴, B. Sirav⁵, S. Varol⁶

¹Department of Biophysics, Faculty of Medicine, Mardin Artuklu University, Mardin, Turkey

²Department of Pathology, Faculty of Medicine, Düzce University, Düzce, Turkey

³Department of Medical Biology, Faculty of Medicine, Kırşehir Ahi Evran University, Kırşehir, Turkey

⁴Department of Electrical and Electronics Engineering, Ege University, Izmir, Turkey

⁵Department of Biophysics, Faculty of Medicine, Gazi University, Ankara, Turkey

⁶Department of Biophysics, Faculty of Medicine, Erciyes University, Kayseri, Turkey

► Original article

ABSTRACT

*Corresponding author:

Mehmet Cihan Yavas, Ph.D.,

E-mail:

mcihanyavas@artuklu.edu.tr

Received: June 2023

Final revised: November 2023

Accepted: December 2023

Int. J. Radiat. Res., July 2024;
22(3): 523-530

DOI: 10.61186/ijrr.22.3.523

Background: We evaluate the effects of radiofrequency electromagnetic field (RF-EMF) on rat brain and testicular tissue using histopathology, comet assay, and real-time quantitative PCR techniques. **Materials and Methods:** Two equal groups of fourteen rats one for sham-control and the other for exposure (n = seven) were created. For a duration of 14 days, the exposure group (2100 MHz, testicular tissue SAR values of 163 mW/kg for 10 g, brain tissue SAR values of 292 mW/kg on average) was subjected to five hours of exposure per day. Evaluations were conducted on tissue gene expression levels, histopathology, and DNA damage to brain tissue. **Results:** The histological examination of brain tissue from the exposed group revealed vascular alterations and significant edema ($p < 0.05$). It was determined that RF radiation-induced much more cellular damage in the exposed group (18.26% tail DNA) than in the control group (4.06% tail DNA). Signs of deterioration in spermatogenic cells in the testicular tissue of the exposed group also changed significantly ($p < 0.05$). The *Bax* and *bcl-2* genes showed a significant difference ($p < 0.05$) in the mRNA level data, whereas the *p53* genes showed no significant change ($p > 0.05$). **Conclusion:** These findings suggest that it may cause some histopathological and cellular damage in brain and testis tissue.

Keywords: 2100 MHz, Brain, Radiation, Histopathological, qRT-PCR, Radiofrequency, Testicular.

INTRODUCTION

Studies show that chronic exposure to cell phone radiofrequency radiation is increasing. We are constantly exposed to RF-radiations; the source is mobile phones ⁽¹⁾.

The widespread use of mobile phones (MP) also makes wireless technology possible. This will result in a rise in environmental radiofrequency radiation sources and a decline in societal health standards. The International Commission for Non-Ionizing Radiation Protection publishes guidelines on this subject ⁽²⁾. The effects of MP radiation exposure on health are quite concerning. As a result of scientific findings, The International Agency for Research on Cancer has classed the radiofrequency radiation associated with MP use as possibly carcinogenic (group 2B) for humans ⁽³⁾.

An RF-radiation applied at different frequencies causes DNA damage since it changes the oxidative and antioxidant balance in the brain tissues of rats ⁽⁴⁾. It has been reported that electromagnetic exposure from MPs may result in significant changes to the

structure of the hippocampus depending on the dose increase ⁽⁵⁾. Research explains that radiofrequency radiation from MP at high frequencies (1800 and 2100 MHz) causes cell damage in the testicles, as well as oxidative stress and DNA damage in rat testicle tissue ⁽⁶⁾. The effects of 3G MP radiation on the rat breeding system have been investigated. In histopathological studies, it is stated that decreases in spermatogenic cells, change the sperm membrane, and induce oxidative stress ⁽⁷⁾. In histological assessments of short-term, radiation exposures from cell phones, it was noted that there was a significant decrease in erratic seminiferous tubules, low spermatogonia, large multinucleated cells, deteriorated spermatozoa, and Leydig cells ⁽⁸⁾. Many countries, such as Germany, France, Austria, and Sweden, propose measures to minimize exposure to MP. Their suggestions are to use a mobile phone in a hands-free mode to reduce radiation to the head and to, keep MP away from the body ⁽⁹⁾.

The researchers explain that after the rat brain is exposed to mobile communication systems, it can experience gene expression, changes in chromatin

structure, and DNA breaks ⁽¹⁰⁾. Nevertheless, pro-apoptotic (bax and p53) and anti-apoptotic (Bcl-2 and Bcl-xl) proteins are being studied to find out how effective apoptosis is ⁽¹¹⁾. Some study results indicate that the rat brain and testis do not alter the anti-apoptotic protein after whole-body exposure ⁽¹²⁾.

The comet method, also known as single-cell gel electrophoresis analysis, is a straightforward method for determining if cells have sustained DNA damage. The approach was refined by Singh et al. in 1988 after the first research by Östling & Johansson in 1984 ⁽¹³⁾. The comet test is an easy-to-use, fast, and inexpensive technique that can detect single- and double-strand breaks at the single-cell level when DNA is denatured. DNA breaks can occur as a result of irradiation, toxic substances, or chemicals. The mentioned method; is stated in scientific reports that it is applied to many areas such as genotoxicity, carcinogenesis, radiotherapy, irradiated food imaging, and environmental bioimaging ⁽¹⁴⁾.

As a result of the innovations brought by technology and the possibility of access, the rate of owning mobile phones is increasing among young people and throughout society. Scientific interest in the potential effects of these fields is increasing, and different scientific results are reported. The different study reports cause confusion and concern. We tried to determine what kind of interaction RF radiation has on the histopathology of brain and testicular tissue, gene expression, and brain tissue genotoxicity level. Thus, after whole-body exposure to 2100 MHz RF radiation, our study's objectives were to examine the histopathological alterations, cellular DNA damage, and gene expression levels in rat brain and testicular tissue.

MATERIALS AND METHODS

Animal

Our study's conduct was authorized by the Gazi University Animal Experiments Local Ethics Committee (permission number: G.Ü. ET-20.026, date of approval, 02.06.2020).

The study comprised 14 male Sprague Dawley rats in good health, ages 4-5 months, and weighed between 240 and 280 g. They were split into two groups: the exposure group (group 2) (2100 MHz RF radiation) and the sham-control group (group 1). Group 2 was exposed to 7 days a week, 5 hours/day, for 14 days ^(50, 51). Rats were taken to plexiglass cages during the experiment. In the study, conditions included 12 - hour light/night periods, room temperature is 21 - 23 °C and humidity is 45 - 50%. Rats are free to access water and pellet feed (ad libitum).

Exposure design

The signal generator for the electromagnetic field

(Rohde & Schwartz, SMBV100A, Germany) and 2100 MHz GSM-like modulated signals were created with a Schwarzbeck, 9120 L3F Horn antenna (Schönau, Germany). The rats and the antenna were five centimeters apart. Rats were housed in 40 × 25 × 10 cm (length × width × depth) plexiglass cages. Radiofrequency radiation measurements of the environment were made in an isolated room with the device turned off. Then, the measurements were taken again in the cage with the device turned on and averaged. All external factors are neutralized. In addition, the antenna distance was taken as a reference from the previous study conducted by Yavaş *et al.* ⁽²¹⁾. Radiofrequency exposures were monitored with Narda EMR 300 device (NARDA, Pfullingen, Germany) and an appropriate electric field probe. RF- radiation measured an average electric field of 38.95 V/m and a power density of 0.402 mW/cm². SAR calculations for brain tissue revealed values of 292 mW/kg for 10 g and 578 mW/kg for 1 g. It was determined to be 163 mW/kg for 10 g and 316 mW/kg for 1 g of testicular tissue. A commercial electromagnetic solver was used to calculate the SAR. 3D volumetric models were used for calculations. Computer modeling was made using computer simulation technology for the horn antenna used for exposure. The experiment protocol and SAR information are given in figure 1(A-C).

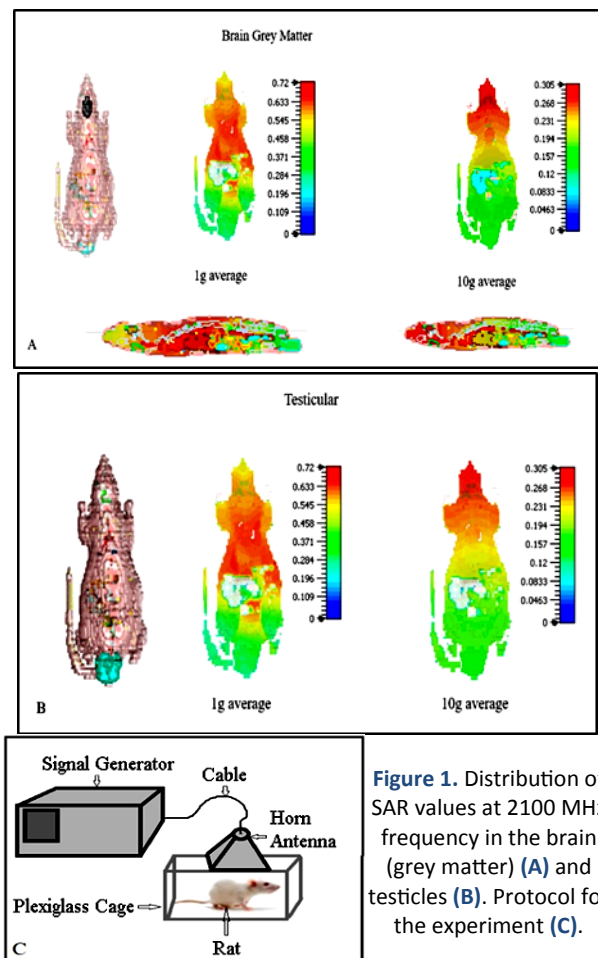


Figure 1. Distribution of SAR values at 2100 MHz frequency in the brain (grey matter) (A) and testicles (B). Protocol for the experiment (C).

Examination of tissue specimens

At the end of the study, group 1 and group 2 were anesthetized, and brain and testicular tissues were removed with a scalpel and placed in formalin. Testicular tissue and brain materials that had been removed were preserved in 10% neutral-buffered formalin (Sigma-Aldrich, Germany). Then, brain and testicular tissue samples were monitored overnight for histopathological evaluation.

Histopathologic evaluation of brain and testicular tissue

The brain and testicular tissues were fixed in paraffin blocks, sectioned into 4 µm thick sections, and stained with hematoxylin and eosin (H & E) following deparaffinization and rehydration. Interstitial fibrosis was also examined using Masson trichrome histochemical staining. With this, p53 immunohistochemical staining was performed for brain tissue (0 for no staining, 1 for focal staining, and 2 for diffuse staining). A light microscope was used for evaluation (Olympus C×41 microscope, Tokyo, Japan) by a pathologist who did not know the exposure groups. We used the following scoring parameters for brain tissue: "vascular changes, necrosis, edema, inflammation, and neuronal degeneration". In scoring for testicular tissue, we used these parameters: "degeneration in spermatogenic cells, damage in seminiferous tubules, interstitial fibrosis, interstitial congestion, interstitial edema, atrophy, and necrosis". Histopathological scoring was performed by determining the highest area for both tissues. The semi-quantitative grading system was divided into three categories: 0 for none, 1 for mild, 2 for moderate, and 3 for severe⁽¹⁵⁾.

Quantitative real-time PCR

Following the kit's instructions, total RNA was extracted from the two tissues by homogenizing them and using the Zymo Quick RNA miniprep kit (Zymo Research, USA). For the synthesis of cDNA from 50ng of RNA per sample, Thermo Scientific, USA's RevertAid First Strand cDNA synthesis kit was utilized. An example of a housekeeping gene was *GAPDH*. Primers, used in the quantitative PCR reaction were: *GAPDH* forward: GAGAAACCTGCCCA GTA, reverse: AGTTGCTGTTGAAGTC; *Bax* forward: CTACAGGGTTTCATCCA reverse: CAGTTCATCTCCAAT TCG; *bcl-2* forward: GTG-GATGACTGAGTACCT reverse: CCAGGAGAAAAGCAAACAGAG; *p53* forward: TATTTAC-CGTCAAGATCC reverse: TGGGCATCCATT AACTCTA. Using PowerUp SYBR Green Master Mix (Thermo Scientific, USA) and the QuantStudio 5 Real-time PCR instrument (ABI, USA), aq PCR experiment was carried out. The comparative Ct ($2^{-\Delta\Delta Ct}$) approach was utilized to ascertain the relative gene expression levels. Software from GraphPad Prism 8.0 (USA) was utilized to do statistical computations.

DNA damage evaluation

We used the neutral comet test method to search for any breaks in the DNA of brain tissue. As a result, comet-like DNA tails were discovered and damage moved from the cell head. Following ethidium bromide staining, DNA damage was observed at 200× magnification using an Olympus BX51 fluorescent microscope (Tokyo, Japan). Images of fifty randomly selected cell nuclei were located using the comet assay program (CASP, publicly available at <http://www.casp.of.pl>, Wroclaw, Poland). Cells that carried tails were thought to be damaged. The DNA damage detected was explained by seven variables. The comet length, olive tail moment, head moment, tail moment, head DNA, tail DNA, and tail length are among them⁽⁵²⁾.

Statistical analyses

The study's outcome was the transfer of data from the Excel file to the statistical program (Statistical Package for Social Sciences version 21.0 software for Windows, Armonk, NY: IBM Corp, USA). The variables' descriptive statistics are shown as a median, or the 25th to 75th percentiles. To examine the scoring outcomes, we employed the Mann-Whitney-U test. The relative gene expression data were statistically calculated using GraphPad Prism 8.0 software (USA). The P-value for all statistical analyses was set at 0.05.

RESULTS

Histopathological findings

Histopathological parameters of the groups were scored in the study. The scoring results between the groups were statistically analyzed. Vascular alterations and edema parameters showed a statistically significant difference in the brain tissue scoring analysis ($p < 0.05$). Necrosis, inflammation, and neuron degeneration metrics did not differ statistically significantly ($p > 0.05$). As a result of p53 immunohistochemistry staining for brain tissue, no change was detected. The brain tissue scoring statistics are displayed in table 1.

Table 1. Histopathological factors of brain tissue

Groups	Histopathological scoring / Median (25th percentile - 75th percentile)				
	Vascular changes	Necrosis	Edema	Inflammation	Neuron degeneration
Group 1	1.0 (0.0-1.0)	0.0 (0.0-0.0)	0.0 (0.0-0.0)	0.0 (0.0-0.0)	1.0 (0.0-1.0)
Group 2	1.0 (1.0-2.0)	0.0 (0.0-1.0)	1.0 (1.0-1.0)	0.0 (0.0-0.0)	1.0 (1.0-2.0)
Group 1	0.030*	0.061	0.002*	0.317	0.202
Group 2					

* A statistically significant $P < 0.05$ was determined.

Hematoxylin and eosin (H & E) stains were employed in the investigation to examine the histological alterations in the group 2 brain tissue. Groups 1 and 2's brain tissues were inspected under a light microscope. In the investigation, group 1 showed no histological alterations. figure 2 shows histopathological changes in the brain tissue of the group 2. In group 2' s brain, vascular alterations, neuron degeneration, edema, and necrosis were noted. (figure 2, A - D)

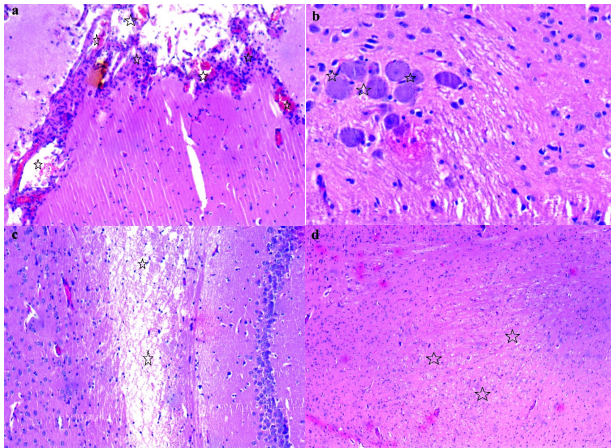


Figure 2. The brain tissue of group 2 (a) showed vascular alterations (asterisks) (H & E, x100). Group 2 (b) brain tissue showed signs of neuron degeneration (asterisks) (H&E, x100). The brain tissue of group 2 (c) showed edema (asterisks) (H & E, x50). The brain tissue of group 2 (d) showed necrosis (asterisks) (H & E, x50).

Histopathological parameters of the groups were scored in the study. The scoring results that were acquired between the groups were subjected to statistical analysis. The testicular tissue scoring statistics are displayed in table 2. The "degeneration in spermatogenic cells" parameter between groups 1 and 2 was found to be statistically significant ($p < 0.05$); however, there was no statistically significant difference found in the parameters related to damage, interstitial congestion, and interstitial edema in seminiferous tubules ($p > 0.05$). Testicular tissue from group 2 did not exhibit fibrosis, necrosis, or atrophy.

Table 2. Testicular tissue histopathological variables

Groups	Histopathological scoring / Median (25th percentile -75th percentile)			
	Spermatogenic cell degeneration	Damage in seminiferous tubules	Interstitial congestion	Interstitial edema
Group 1	1.0 (0.0-1.0)	0.0 (0.0-0.0)	1.0 (1.0-2.0)	0.0 (0.0-1.0)
Group 2	1.0 (1.0-1.0)	1.0 (0.0-1.0)	1.0 (2.0-2.0)	1.0 (1.0-2.0)
Group 1				
Group 2	0.044*	0.081	0.122	0.116

* A statistically significant $P < 0.05$ was determined.

In the study, hematoxylin and eosin (H & E) stains were used for histopathological changes in the testicular tissue of the group 2. In figure 3, histopathological changes in the testicular tissue of the group 2 are given. In the examination made under the light microscope, it was observed that the testicular tissue of the group 1 had a normal

structure and its structural components were normal. In the testicular tissue of the group 2, interstitial congestion, edema, degeneration in spermatogenic cells, and damage in the seminiferous tubules were seen (figure 3, A - F).

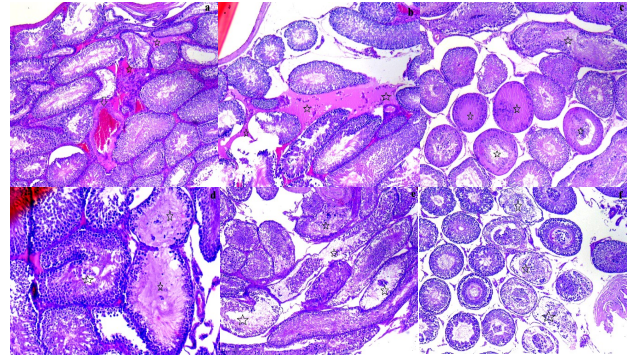


Figure 3. In the group 2, interstitial congestion (arrow) and edema (asterisks) were observed in testicular tissue (a, b) (H & E, x50). In the group 2, degeneration (asterisks) was observed in spermatogenic cells in testicular tissue (c, d) (H & E, x50; H & E, x200). In the group 2, damage to the seminiferous tubules (asterisks) was observed in the testicular tissue (e, f) (H & E, x50).

Real-time quantitative polymerase chain reaction (PCR) results

We investigated the levels of gene expression in the testicular and brain tissues in rats that were exposed to a whole body of stimulants. Using quantitative real-time PCR, three genes (*p53*, *bcl-2*, and *bax*) were measured in separate samples from groups 1 and 2. Pro-apoptotic *bax* gene expression levels differed statistically significantly between groups 1 and 2, as figures 4 and 5 demonstrate. Following radiation, there was a substantial drop in Bax mRNA levels in the brain tissue as compared to group 1 ($P = 0.02$, *). There were no statistically significant variations found for the *p53* or *bcl-2* genes (figure 4). Comparable outcomes were seen for testicular tissues; *bax* gene mRNA levels were considerably reduced ($P = 0.03$, *), but *p53* and *bcl-2* gene expression levels were proven to be statistically indifferent (figure 5).

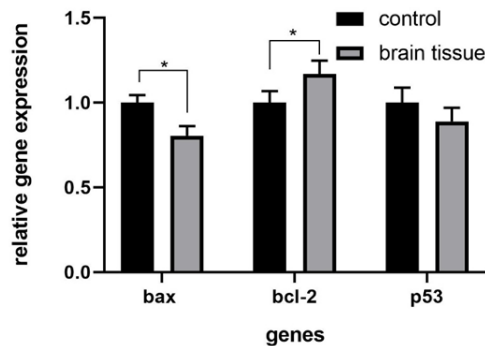


Figure 4. The *p53*, *bax*, and *bcl-2* gene expression levels in groups 1 and 2. Following radiation, there was a substantial drop in *bax* mRNA levels in the brain tissue as compared to group 1 ($p = 0.02$, *). Additionally, there is a significant rise in brain tissue *bcl-2* mRNA levels ($p = 0.02$, *). On the other hand, there was no discernible variation in the levels of *p53* gene expression.

Damage to Brain DNA

In brain tissue, cellular DNA damage was evaluated by means of a neutral comet assay. We assessed seven comet parameters: olive tail moment (arbitrary unit), head DNA (%), tail DNA (%), length comet (μm), length head (μm), and length tail (μm). Group 2 experienced an increase in comet

parameters (except head DNA) in comparison to the control group. Group 2 showed a decrease in head DNA compared to the control group. According to table 3 and figure 6 of our results, group 2's brain tissue had significantly more DNA damage than group 1's.

Table 3. The impact of radiofrequency radiation at 2100 MHz on comet characteristics in the brain of rats.

Groups	Head Length (μm)	Tail Length (μm)	Comet Length (μm)	% of Head DNA	DNA Tail (%)	Moment of Tail	Olive tail moment
Group 1 (Mean \pm SD)	129.0 \pm 19.5	24.80 \pm 9.5	153.80 \pm 25.6	95.94 \pm 0.9	4.06 \pm 0.9	1.22 \pm 0.4	2.16 \pm 0.8
Group 2 (Mean \pm SD)	219.00 \pm 19.3	138.80 \pm 28.7	359.80 \pm 39.6	81.76 \pm 1.3	18.24 \pm 1.3	24.26 \pm 6.7	23.70 \pm 4.4
p*	<0,001	<0,001	<0,001	<0,001	<0,001	<0,001	<0,001

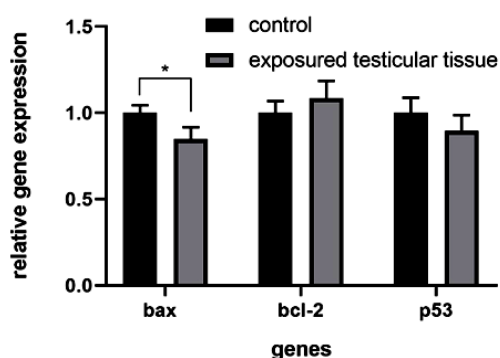


Figure 5. *Bax*, *bcl-2*, and *p53* gene expression levels in groups 1 and 2 (P=0.03, *), while *p53* and *bcl-2* gene expression levels were shown to be statistically indifferent.

DISCUSSION

Human health is impacted by extremely low-frequency electromagnetic fields that we utilize and are exposed to daily. However, as a result of whole-body exposure (2100 MHz) on rats, there are data in the analysis of their serum that indicates it does not cause any adverse effects on oxidative stress and thiol/disulfide homeostasis (21). Meanwhile, reports from experimental studies show that these areas cause histopathological changes, increase oxidative stress, cause toxic effects in the brain, and affect some serum biochemistry parameters (16, 20, 53). Keeping mobile phones near the brain during discussions and frequently near the reproductive organs raises severe concerns. Numerous research studies have shown findings indicating that electromagnetic fields generated by cell phones have an impact on the body, prevent neural stem cells from forming during embryonic development, and have an impact on the neurological and reproductive health of fetuses (22).

As a result of the development of technology and the increase in the frequency of using mobile phones, more exposure occurs. For this reason, in our study, we designed the 5-hour daily exposure system in accordance with the literature. Aydođan *et al.* established a 2100 MHz exposure system for 6 hours a day, and Koca *et al.* established a 900 MHz exposure system for 8 hours a day (50, 51).

Researchers have reported that Wistar rats had

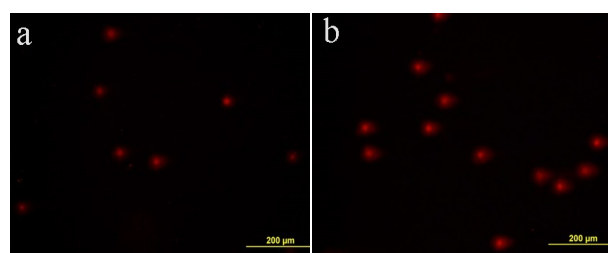


Figure 6. (A) DNA undamaged brain cells (Tail DNA is % 4.06). (B) DNA damaged brain cells (Tail DNA is %18.24). (Ethidium bromide staining, \times 400).

damaged brain cells as a result of being exposed to 900 MHz GSM radiofrequency radiation for 90 days (23). It has been reported that the number and size of the vacuoles increase in the brain tissues as does the vacuolization in the brain tissues of the male Wistar rats left on the 900 MHz (2 months, 6 hours a day) radiofrequency exposure (24). 900 MHz radiation (14 and 28 days, 3 hours a day) was applied to male Wistar rats and was found to cause degeneration and edema in neuronal cell organelles after 28 days of exposure. In addition, the blood-brain barrier permeability was affected (25). It has been stated that radiation exposure of 2100 MHz mobile phones 4 hours a day for three months increases intracellular oxidative stress and creates neuron degeneration (26). The researchers investigated the effect of the oxidative DNA damage on the 3G mobile phone 2100 MHz radiofrequency domain. In groups exposed to the study results, they reported an increase in brain damage after 10 days of exposure and a decrease in brain damage after 40 days of exposure (27). There are serious concerns about the effects of MP use on the human body. In vitro, and animal model studies have been conducted to investigate these effects. Research has demonstrated that radiofrequency radiation can alter central nervous system nerve cells, leading to alterations in neuronal cell apoptosis, nerve myelin function, and ion channels (28). Rats were exposed to both acute (1 week) and chronic (10 weeks) radiofrequency electromagnetic radiation at 900 and 2100 MHz. The study's findings showed that rats

exposed to 2100 MHz radiation had considerably higher hippocampus activity than rats subjected to 900 MHz radiation⁽²⁹⁾. Albino mice were given 1800–2100 MHz radiation for three months, 30 - 60 minutes a day. The study revealed that the hippocampal region of the mice was damaged and had fewer neurons, which may have an impact on learning and memory⁽³⁰⁾. Electromagnetic field exposure (2 months, 1 hour per day) of 2G, 3G, and 4G mobile phones was performed on the purkinje cell layer of the rats. In the study, it was stated that 3G and 4G caused more damage⁽³¹⁾. Most of the scientific study reports on RF radiation originating from mobile phones indicate that these fields hurt brain tissue. In our study (as seen in table 1 and figure 2), it was observed that brain tissue formed vascular changes (congestion, mild capillary proliferation, erythrocyte extravasation) and edema histomorphological findings. As a result of the statistical analysis, necrosis, inflammation, and neuron degeneration were not found to be statistically significant. Our study data showed that there may be some changes in brain tissue, but the GSM-like RF radiation does not have a significant change in the brain.

Two hours of daily exposure to 2.45 GHz microwave radiation were produced for thirty days. The brain, liver, testicle, kidney, and spleen tissues of the exposed group showed histological alterations in comparison to the control group⁽³⁵⁾ Ozguner *et al.* investigated the morphological change in the reproductive organ after electromagnetic exposure. In the study, a decrease in seminiferous tubular diameter and epithelial thickness was reported after exposure⁽³⁶⁾. They reported that the exposure of 3G radiofrequency radiation to male Wistar rats for 60 days, 2 hours a day, resulted in DNA damage, a decrease in seminiferous tubules and testicular weight, and an increase in lipid peroxidation in sperm cells⁽³⁷⁾.

It has been reported that the average tubular and germinal tissue volume, seminiferous tubule diameter, and height of the germinal epithelium in the testicular tissues of the exposure group of 890-915 MHz mobile phone-induced electromagnetic field, (male wistar albino rats), have been reported to have morphological and histological change⁽³⁸⁾. It has been stated that the effect of a 900 MHz EMF exposure (28 days, 60 minutes a day) on the testicle of the rat is most prominent in the interstitial tissue, seminiferous epithelium, and tubules in the experimental group⁽³⁹⁾. In the study conducted by Odacı *et al.* in a histopathological analysis of testicular tissue of 900 MHz EMF, vacuoles in the basal membrane of the seminiferous tubules and edema in the intertubular space were detected in the testicles of the EMF group of rats⁽⁴⁰⁾. In our study (table 2 and figure 3), as a result of histopathological evaluations of the group 1 and group 2' s rat testicle

tissues, spermatogenic cell degeneration, interstitial congestion, edema, and damage to the seminiferous tubules were detected. Just the spermatogenic cell degradation measure showed a statistically significant difference. Our study findings support the histopathological data.

Reports are presented stating that EMR from Wi-Fi and mobile phones affect the male and female reproductive system, causing oxidative stress. However, there are reports that there is no risk of male and female infertility from exposures related to electromagnetic radiation⁽⁴¹⁾. There was no significant change in the morphology of the testicles, epididymis, and prostate as a result of the exposure to an 1800 MHz GSM-like electromagnetic field (10 times and 2 hours / day)⁽⁴²⁾. In their study, Dasdag *et al.* reported that 20 minutes of cell phone radiofrequency radiation did not cause a significant change in the testicular structure and function of Wistar rats. They also showed that sperm count, morphology, and testicles did not affect the seminiferous tubule diameters⁽⁴³⁾. The researchers applied exposure to mobile phone radiation at a frequency of 890–915 MHz for 1 hour/day for 45 days. As a result of histopathological evaluations, they did not detect a significant difference between the groups for caspase 3 and ki - 67. In addition, there was no abnormality in the exposed group's interstitial connective tissue and histological appearance of seminiferous tubules⁽⁴⁴⁾. A review of the literature reveals that certain study reports claim that radiofrequency electromagnetic fields do not effect testicular tissue. According to statistical analysis, there was no discernible difference between groups 1 and 2 in our study's findings of seminiferous tubule degeneration, interstitial congestion, edema, fibrosis, necrosis, and atrophy (figure 3).

Researchers did not see a significant difference in the *p53* evaluation of radiofrequency radiation at frequencies between 1900- 2100 MHz⁽³³⁻³⁴⁾. In our study, it was seen that there was no significant damage and change after *p53* analysis for evaluation after immunohistochemical staining.

Research has been done on the effects of cell phone exposure on BALB/c mice's cerebellum. The study's findings demonstrate that *bcl-2* and *p53* gene expression levels are not affected by mobile phone radio waves. After a month of 20 minutes a day of exposure to the brain of male Sprague-Dawley rats, researchers found no change in the anti-apoptotic *bcl-2* protein found in the mitochondria⁽¹²⁾. Long-term exposure to mobile phone RF-radiation can cause significant changes in the balance of *bax / bcl2* mRNA expression in the hippocampus of mice⁽⁴⁶⁾. However, they also found that the *p21* gene expression level increased and the *bax* gene expression level decreased in comparison to the control group⁽⁴⁵⁾.

Bax and *p53* genes are pro-apoptotic genes,

inducing apoptosis, which is known to be disabled in cancer development⁽⁴⁷⁾. On the contrary, the *bcl-2* gene is a member of the pro-oncogene family and inhibits apoptosis, increasing cell viability⁽⁴⁸⁾. Gene expression results showed an important increase in *bcl-2* mRNA levels in brain tissue ($p < 0.05$) as expected. Our results were in line with the literature considering the pro-apoptotic activity of *bax*, which is shown to be decreased in both tissues significantly ($p < 0.05$) because of expected DNA damage due to radiation⁽⁴⁹⁾. Our results (figures 4 and figure 5), did not show any significant difference in *p53* gene expression levels, which may be related to exposure times. It should be considered that longer exposure times may result in differently expressed mRNA levels.

For more than a year, rats were subjected to radiation at a frequency of 2.4 GHz. Scientists assessed DNA damage in the skin, kidney, liver, and brain. In this study (table 3 and figure 6), a sharp increase in comet parameters (except tail DNA) was observed in the exposure group brain as compared to the control rat brain⁽³²⁾. The tail DNA values of the brain, kidney, liver, and skin tissues of the rats increased more than in the control group. There was DNA damage at the single-cell level in the exposure groups.

CONCLUSION

The effect of a high daily 2100 MHz RF- radiation on rat brain and testicular tissue was investigated in our study. Our current study results show that it may appear to cause some minor changes in brain and testicle tissue. In terms of DNA damage, it has been noted that brain tissue is exposed to 2100 MHz RF radiation to investigate the impacts of both short- and long-term exposures at the molecular level over the same daily length, more thorough research is necessary.

ACKNOWLEDGEMENTS

None.

Funding: None.

Ethical approval: The ethical approval for this work was obtained from the Gazi University Animal Experiments Local Ethics Committee (approved number: G.Ü. ET-20.026), Ankara, Turkey, and it was carried out in the Laboratory Animal Breeding and Experimental Research (GUDAM) Center.

Conflicts of interest: The authors of this article affirm that they have none about this topic.

Author contribution: MCY: idea and design of the article; data acquisition; surface sample collection; data interpretation; article drafting and critical revision; final approval. AK: completed the article's final approval, revision, and histopathological evaluations. EC: The article was revised, approved as

its whole, and evaluated by qPCR analysis. MCY, SV: The article's DNA damage study. KY, BS: SAR analysis, installation of RF systems, article revision, and final approval.

REFERENCES

- Singh KV, Gautam R, Meena R, et al (2020) Effect of mobile phone radiation on oxidative stress, inflammatory response, and contextual fear memory in Wistar rat. *Environ. Sci Pollut Res* **27**: 19340-19351, PMID: 32212071, <https://doi.org/10.1007/s11356-020-07916-z>
- ICNIRP (2020) Frequency asked questions on the ICNIRP Guidelines for Limiting Exposure to Electromagnetic Fields (100 kHz-300 GHz). *Health Physics*, **118**(5): 483-524,
- IARC (2011) IARC classifies radiofrequency electromagnetic fields as possibly carcinogenic to humans. (online access: 23 January 2021) http://www.iarc.fr/en/media-centre/pr/2011/pdfs/pr208_E.pdf
- Alkis ME, Bilgin HM, Akpolat V, et al (2019) Effect of 900-, 1800-, and 2100-MHz radiofrequency radiation on DNA and oxidative stress in brain. *Electromagn Biol Med*, **38**(1): 32-47, <https://doi.org/10.1080/15368378.2019.1567526>
- El-Kafoury B, Hamam GG, Ezzat SF (2020) Effect of Exposure to different doses of cell phone-electromagnetic waves on the hippocampus and testis of Adult Albino Rats: A histological study. *Egyptian Journal of Histology*, **42**(4): 956-973, <https://dx.doi.org/10.21608/ejh.2019.12231.1125>
- Alkis ME, Akdag MZ, Dasdag S, et al (2019) Single-strand DNA breaks and oxidative changes in rat testes exposed to radiofrequency radiation emitted from cellular phones. *Biotechnol Biotechnol Equip*, **33**(1): 1733-1740, <https://doi.org/10.1080/13102818.2019.1696702>
- Gautam R, Singh KV, Nirala J, et al (2019) Oxidative stress-mediated alterations on sperm parameters in male Wistar rats exposed to 3G mobile phone radiation. *Andrologia*, **51**(3): e13201, PMID: 30461041, DOI: <https://doi.org/10.1111/and.13201>
- Bin-Meferij MM, El-Kott AF (2015) The radioprotective effects of Moringa oleifera against mobile phone electromagnetic radiation-induced infertility in rats. *Int J Clin Exp Med*, **8**(8): 12487-12497, PMID: 26550159, <http://www.ncbi.nlm.nih.gov/pmc/articles/pmc4612844/>
- Dagli R, Hans R (2015) Effect of mobile phone radiations on oral health. *J Int Oral Health*, **7**(1): i-ii, PMID: 25709374, <https://pubmed.ncbi.nlm.nih.gov/25709374>
- Belyaev IY, Koch CB, Terenius O, et al (2006) Exposure of rat brain to 915 MHz GSM microwaves induces changes in gene expression but not double stranded DNA breaks or effects on chromatin conformation. *Bioelectromagnetics*, **27**(4): 295-306, PMID: 16511873, DOI: <https://doi.org/10.1002/bem.20216>
- Shahin S, Singh SP, Chaturvedi CM (2018) 2.45 GHz microwave radiation induced oxidative and nitrosative stress mediated testicular apoptosis: Involvement of a p53 dependent bax-caspase-3 mediated pathway. *Environ Toxicol*, **33**(9): 931-945, PMID: 29968967, DOI: <https://doi.org/10.1002/tox.22578>
- Yilmaz F, Dasdag S, Akdag MZ, et al (2008) Whole-body exposure of radiation emitted from 900 MHz mobile phones does not seem to affect the levels of anti-apoptotic bcl-2 protein. *Electromagn Biol Med*, **27**(1): 65-72, PMID: 18327715, DOI: <https://doi.org/10.1080/15368370701878978>
- Singh Narendra P, McCo, Michael T, Tice Raymond R, Schneider Edward L (1988) A simple technique for quantitation of low levels of DNA damage in individual cell. *Exp Cell Res*, **175**(1): 184-191, PMID: 3345800, [https://doi.org/10.1016/0014-4827\(88\)90265-0](https://doi.org/10.1016/0014-4827(88)90265-0)
- Cordelli E, Bignami M, Pacchierotti F (2021) Comet assay: a versatile but complex tool in genotoxicity testing. *Toxicol Res*, **10**: 68-78, PMID: 33613974, <https://doi.org/10.1093/toxres/tfaa093>
- He J, Ji X, Li Y, et al (2016) Subchronic exposure of benzo(a)pyrene interferes with the expression of Bcl-2, Ki-67, C-myc and p53, Bax, Caspase-3 in sub-regions of cerebral cortex and hippocampus. *Exp Toxicol Pathol*, **68**(2-3): 149-156, PMID: 26679980, <https://doi.org/10.1016/j.etp.2015.11.007>
- Akdag MZ, Dasdag S, Ulukaya E, et al (2010) Effects of extremely low-frequency magnetic field on caspase activities and oxidative stress values in rat brain. *Biol Trace Elem Res*, **138**(1-3): 238-249, PMID: 20177816, <https://doi.org/10.1007/s12011-010-8615-3>
- Doğan MS, Yavaş MC, Günay A, et al (2017) The protective effect

- of melatonin and Ganoderma lucidum against the negative effects of extremely low frequency electric and magnetic fields on pulp structure in rat teeth. *Biotechnol Biotechnol Equip*, **31(5)**: 979-988, <https://doi.org/10.1080/13102818.2017.1358668>
18. Yavaş MC, Akpolat V, Devenci E, et al (2018) Determining the effect of an electromagnetic field generated by a high voltage power line on rat spermatogonia cells. *Dicle Medical Journal*, **45(4)**: 447-461, <https://doi.org/10.5798/dicletip.497923>
 19. Tanik A, Yavas MC (2019) Protective Effect of Melatonin and Ganoderma Lucidum Against the Negative Effects of Extremely Low Frequency Electromagnetic Fields on Alveolar Bone in Rats: An Experimental Animal Study. *Anal Quant Cytol Histol*, **41(2)**: 55-66.
 20. Yavaş MC (2020) Changes in the serum of individuals exposed to extremely low frequency electromagnetic fields for a long time. *Adiyaman University Health Science Journal*, **6(1)**: 13-18, <https://doi.org/10.30569/adiyamansaglik.558935>
 21. Yavaş MC, Yeğin K, Oruç K, et al (2021) Analysis of thiol/disulphide homeostasis and oxidant-antioxidant status as a result of exposure to radio-frequency electromagnetic fields. *Electromagn Biol Med*, **40(1)**: 84-91, <https://doi.org/10.1080/15368378.2021.1874970>
 22. Kaplan S, Deniz OG, Önger ME, et al (2016) Electromagnetic field and brain development. *J Chem Neuroanat*, **75**: 52-61, PMID: 26686296, <https://doi.org/10.1016/j.jchemneu.2015.11.005>
 23. Đinđić B, Sokolović D, Krstić D, et al (2010) Biochemical and histopathological effects of mobile phone exposure on rat hepatocytes and brain. *Acta Med Mediterr*, **49(1)**: 37-42,
 24. Shahabi S, Hassanzadeh Taji I, Hoseinnezhaddarzi M, et al (2018) Exposure to cell phone radiofrequency changes corticotrophin hormone levels and histology of the brain and adrenal glands in male Wistar rat. *Iran J Basic Med Sci*, **21**: 1269-1274, PMID: 30627371, <https://doi.org/10.22038/2Fijbms.2018.29567.7133>
 25. Tang J., Zhang Y, Yang L, et al (2015) Exposure to 900 MHz electromagnetic fields activates the mdk-1/ERK pathway and causes blood-brain barrier damage and cognitive impairment in rats. *Brain Res*, **1601**: 92-101, PMID: 25598203, <https://doi.org/10.1016/j.brainres.2015.01.019>
 26. Sharma A, Sharma S, Shrivastava S, et al (2019) Mobile phone induced cognitive and neurochemical consequences. *J Chem Neuroanat*, **102**: 101684, PMID: 31553920, <https://doi.org/10.1016/j.jchemneu.2019.101684>
 27. Sahin D, Ozgur E, Guler G, et al (2016) The 2100 MHz radiofrequency radiation of a 3G-mobile phone and the DNA oxidative damage in brain. *J Chem Neuroanat*, **75**: 94-98, PMID: 26775761, <https://doi.org/10.1016/j.jchemneu.2016.01.002>
 28. Kim JH, Lee JK, Kim HG, et al (2019) Possible effects of radiofrequency electromagnetic field exposure on central nerve system. *Biomol Ther*, **27(3)**: 265, PMID: 30481957, <https://doi.org/10.4062/biomolther.2018.152>
 29. Gökçek-Saraç Ç, Er H, Kencebay Manas C, et al (2017) Effects of acute and chronic exposure to both 900 MHz and 2100 MHz electromagnetic radiation on glutamate receptor signalling pathway. *Int J Radiat Biol*, **93(9)**: 980-989, PMID: 28565929, <https://doi.org/10.1080/09553002.2017.1337279>
 30. Krishna KG, Venkateshu KV, Sridevi NS (2019) Effect of 1800-2100 MHz electromagnetic radiation on learning-memory and hippocampal morphology in swiss albino mice. *J Clin Diagnostic Res*, **13(2)**: AC14-AC17, <https://doi.org/10.7860/JCDR/2019/39681.12630>
 31. Ali M, Butt SA, Hamid S (2017) Effect of electromagnetic field from 2G, 3G and 4G mobile phones on the organization of purkinje cell layer of rat cerebellum. *Pakistan Armed Forces Medical Journal*, **67(3)**: 462-66.
 32. Akdağ MZ, Daşdağ S, Cantürk F, et al (2016) Does prolonged radiofrequency radiation emitted from Wi-Fi devices induce DNA damage in various tissues of rats? *J Chem Neuroanat*, **75**: 116-122, PMID: 26775760, <https://doi.org/10.1016/j.jchemneu.2016.01.003>
 33. Yılmaz A, Yılmaz N, Serarslan Y, et al (2014) The effects of mobile phones on apoptosis in cerebral tissue: an experimental study on rats. *Eur Rev Med Pharmacol Sci*, **18(7)**: 992-1000, PMID: 24763879
 34. Dasdag S, Akdag MZ, Ulukaya E, et al (2009) Effect of mobile phone exposure on apoptotic glial cells and status of oxidative stress in rat brain. *Electromagn Biol Med*, **28(4)**: 342-354, PMID: 20017625, <https://doi.org/10.3109/15368370903206556>
 35. Chauhan P, Verma HN, Sisodia R, et al (2017) Microwave radiation (2.45 GHz)-induced oxidative stress: Whole-body exposure effect on histopathology of Wistar rats. *Electromagn Biol Med*, **36(1)**: 20-30, PMID: 27362544, <https://doi.org/10.3109/15368378.2016.1144063>
 36. Ozguner M, Koyu A, Cesur G, et al (2015) Biological and morphological effects on the reproductive organ of rats after exposure to electromagnetic field. *Saudi Med J*, **26(3)**: 405-410, PMID: 15806208.
 37. Kumar S, Jay PN, Behari J, et al (2014) Effect of electromagnetic irradiation produced by 3G mobile phone on male rat reproductive system in a simulated scenario. *Indian J Exp Biol*, **52**: 890-897, PMID: 25241589.
 38. Çetkin M, Kızılkın N, Demirel C, et al (2017) Quantitative changes in testicular structure and function in rat exposed to mobile phone radiation. *Andrologia*, **49(10)**: 10, <https://doi.org/10.1111/and.12761>
 39. Yahyazadeh A, Altunkaynak BZ, Kaplan S
 40. (2020) Biochemical, immunohistochemical and morphometrical investigation of the effect of thymoquinone on the rat testis following exposure to a 900-MHz electromagnetic field. *Acta Histochem*, **122(1)**: 151467, PMID: 31784235, <https://doi.org/10.1016/j.acthis.2019.151467>
 41. Odacı E and Özyılmaz C (2015) Exposure to a 900 MHz electromagnetic field for 1 hour a day over 30 days does change the histopathology and biochemistry of the rat testis. *Int J Radiat Biol*, **91(7)**: 547-554, PMID: 25786704, <https://doi.org/10.3109/09553002.2015.1031850>
 42. Nazıroğlu M, Yüksel M, Köse SA, Özkaya MO (2013) Recent Reports of Wi-Fi and mobile phone-induced radiation on oxidative stress and reproductive signaling pathways in females and males. *J Membr Biol*, **246**: 869-875, PMID: 24105626, <https://doi.org/10.1007/s00232-013-9597-9>
 43. Forgács Z, Somosy Z, Kubinyi G, et al (2006) Effect of whole-body 1800 MHz GSM-like microwave exposure on testicular steroidogenesis and histology in mice. *Reprod Toxicol*, **22(1)**: 111-117, PMID: 16434166, <https://doi.org/10.1016/j.reprotox.2005.12.003>
 44. Dasdag S, Akdag MZ, Aksin F, et al (2003) Whole body exposure of rats to microwaves emitted from a cell phone does not affect the testes. *Bioelectromagnetics*, **24(3)**: 182-188, PMID: 12669301, <https://doi.org/10.1002/bem.10083>
 45. Tumkaya L, Kalkan Y, Bas O, et al (2016) Mobile phone radiation during pubertal development has no effect on testicular histology in rats. *Toxicol Ind Health*, **32(2)**: 328-336, PMID: 24097363, <https://doi.org/10.1177/0748233713500820>
 46. Ghatei N, Nabavi AS, Toosi MHB, et al (2017) Evaluation of bax, bcl-2, p21 and p53 genes expression variations on cerebellum of BALB/c mice before and after birth under mobile phone radiation exposure. *Iran J Basic Med Sci*, **20(9)**: 1037-1043, PMID: 29085599, <https://doi.org/10.22038/ijbms.2017.9273>
 47. Tohidi FZ, Sadr-Nabavi A, Haghiri H, et al (2020) Long-term exposure to electromagnetic radiation from mobile phones can cause considerable changes in the balance of Bax/Bcl2 mRNA expression in the hippocampus of mice. *Electromagn Biol Med*, **40(1)**: 131-137, PMID: 33081559, <https://doi.org/10.1080/15368378.2020.1830793>
 48. Brown J and Attardi L (2005) The role of apoptosis in cancer development and treatment response. *Nat Rev Cancer*, **5**: 231-237, PMID: 15738985, <https://doi.org/10.1038/nrc1560>
 49. Saraga-Babic M, Bazina M, Vukojevic K, et al (2008) Involvement of pro-apoptotic and anti-apoptotic factors in the early development of the human pituitary gland. *Histol Histopathol*, **23(10)**: 1259-68, PMID: 18712678, <https://doi.org/10.14670/hh-23.1259>
 50. MacFarlane M, Williams AC (2004) Apoptosis and disease: a life or death decision. *EMBO Rep*, **5**: 674-678, PMID: 15218528, <https://doi.org/10.1038/2Fsj.embor.7400191>
 51. Koca O, Gökçe AM, Öztürk MI, Ercan F, Yurdakul N, & Karaman MI (2013) Effects of intensive cell phone (Philips Genic 900) use on the rat kidney tissue. *Urology Journal*, **10(2)**: 886-891.
 52. Aydoğan F, Unlu İ, Aydın E, Yumusak N, Devrim E, Samim EE, ... & Seyhan N (2015) The effect of 2100 MHz radiofrequency radiation of a 3G mobile phone on the parotid gland of rats. *American Journal of Otolaryngology*, **36(1)**: 39-46. <https://doi.org/10.1016/j.amjoto.2014.10.001>
 53. Akdag M, Dasdag S, Canturk F, Akdag MZ (2018) Exposure to non-ionizing electromagnetic fields emitted from mobile phones induced DNA damage in human ear canal hair follicle cells. *Electromagn Biol Med*, **37**: 66-75. <https://doi.org/10.1080/15368378.2018.1463246>
 54. Ozmen MF, Seker U, Yavas MC, Cirit U, Akdag M (2021) Effects of ganoderma lucidum and melatonin on sperm in rats exposed to electromagnetic field. *Int J Radiat Res*, **19(1)**: 121-126. <https://doi.org/10.29252/ijrr.19.1.121>