



## **The Adverse Effect of Mobile Phone Radiations on Dorsal Root Ganglion of Albino Rats**

**Faisal Taufiq<sup>1</sup>, Mohammed Bhilal Babu<sup>1</sup>, Aqeel Ahmad<sup>2</sup>,  
Mohammed Ejaz Ahmed Shariff<sup>3</sup>, Nouredaim Elnoman Elbadawi<sup>2\*</sup>  
and Semmal Syed Meerasa<sup>4</sup>**

<sup>1</sup>Department of Anatomy, College of Medicine, Shaqra University, Shaqra, Saudi Arabia.

<sup>2</sup>Department of Medical Biochemistry, College of Medicine, Shaqra University, Shaqra, Saudi Arabia.

<sup>3</sup>Department of Physiology, Travancore Medical College, Kollam, India.

<sup>4</sup>Department of Physiology, College of Medicine, Shaqra University, Shaqra, Saudi Arabia.

### **Authors' contributions**

*This work was carried out in collaboration among all authors. Authors FT and NEE designed the study, performed the statistical analysis, wrote the protocol and wrote the first draft of the manuscript. Authors MBB, MEAS and AA managed the analyses of the study. Authors FT and SSM managed the literature searches. All authors read and approved the final manuscript.*

### **Article Information**

DOI: 10.9734/JPRI/2021/v33i1331266

Editor(s):

(1) Dr. Aurora Martínez Romero, Juarez University, Mexico.

Reviewers:

(1) Jose-Miguel Esparza-Miñana, Universidad Católica de Valencia. Hospital de Manises, Spain.

(2) Elham Foroozandeh, Islamic Azad University, Iran.

Complete Peer review History: <http://www.sdiarticle4.com/review-history/66168>

**Original Research Article**

**Received 03 January 2021**

**Accepted 08 March 2021**

**Published 19 March 2021**

### **ABSTRACT**

**Objectives:** To assess the effect of Mobile Phone Radio Frequency Electromagnetic Radiation (RF-EMR) on the histological structure of dorsal root ganglia in albino rats.

**Methods:** Twenty-four albino rats divided into one control and three experimental groups were studied for four weeks. The experimental groups were exposed to three different levels of RF-EMR through complete missed calls of 80,120 and160 calls per day respectively, using a GSM mobile phone of 0.9GHz to1.8 GHz in silent mode. The dorsal root ganglia of the sacrificed Rats were examined under light and transmission electron microscope (TEM).

**Results:** Dorsal root ganglions of exposed rats showed considerable histological changes like reduction in cell size, condensation of cytoplasm, peripherally located heterochromatin nucleus, loss of nucleolus and densely packed myelinated nerve fibers. No such changes were observed in control rats.

\*Corresponding author: E-mail: [nouredaim@hotmail.com](mailto:nouredaim@hotmail.com);

**Conclusion:** Dorsal root ganglionic cells showed enduring and continuous changes when exposed to RF-EMR. The severity of histomorphological changes was dose-dependent, which increased constantly with radiation dosage increment. It might be fair to conclude that degenerative changes in the Dorsal Root Ganglion of the spinal cord, could be attributed to the long-term exposure to RF-EMR.

*Keywords: Albino rats; dorsal root ganglion; mobile phone radiofrequency electromagnetic radiations; spinal ganglion; histomorphological changes.*

## 1. INTRODUCTION

We live in an era where mobile phones have steadily and rapidly become one of the human necessities. Our generation considers mobile phones as a blessing to the human race. But along with the blessings comes the adversary of Radio frequencies – Electromagnetic radiations (RF-EMR), a technology on which mobile phones function. Radio frequencies are non-ionizing radiation ranging from 3Hz to 3THz, while mobile communication services typically use 900 MHz to 2.1GHz wavelengths for calling purposes [1]. The human race's exposure to RF-EMR has significantly increased in the past decade due to the aggressive expansion of mobile phone technologies. In 2015 world had more than seven billion mobile phone subscriptions which is growing at an exponential rate [2]. The cautionary regarding possible damaging effects on health has nevertheless been expressed since the advent of RF-EMR. This all-round access to emerging technology has contributed to gigantic-scale health studies worldwide [3].

Dorsal root ganglion (DRG) is a collection of nerve cell bodies of sensory neurons in the dorsal root of a spinal nerve, which conveys sensory signals into the spinal cord. Other components of DRG are nerve fibers, satellite cells, macrophages, and fibroblast cells. DRG can be regarded as a gray matter of the spinal cord that became translocated to the periphery [4]. Although several investigational findings had already been accomplished in connection to RF-EMR with unfavorable results on the nervous system [5], yet there is a lack of information regarding the impact of RF-EMR on the dorsal root ganglia. We endeavored to deliberate the possible anticipated toxic impact of RF-EMR generated by mobile phones on the histological structure of dorsal root ganglia in albino rats.

## 2. MATERIALS AND METHODS

The study included twenty-four inbred adult healthy 180 - 200 grams weighing albino rats of both genders [6]. Three or four rats were maintained in each (36 cm × 23 cm × 21 cm)

cage and fed with standard form pellet lab diet and water ad libitum. Temperature has been maintained at 26 C<sup>0</sup> in all cages by using a temperature controller (ATC-2000 world precision instruments (WPI) company, china). The rats were divided into four experimental groups (control, T80, T120, T160) based on the dosage of Rf-EMR exposure they would receive throughout the experimental span. To achieve Rf-EMR exposure, a 0.9 to 1.8 GHz mobile phone in complete silent mode with both ring tone and vibration switched off was kept in the cage and a full missed call was given to the mobile phone. The control group rats were not exposed to any missed calls. While T80, T120, and T160 groups were exposed to 80, 120 and 160 missed calls respectively per day for four weeks [7]. Later all experimental animals were sacrificed, rodent tissue was cleansed with salt and preserved by injecting Karnovsky fixative. After tissue fixation was evident, the vertebral column from cervical to the lumbar region was dissected through the back. The spinal cord alongside dorsal root ganglion of the experimental and control rats was delicately expelled and promptly immersed in Karnovsky fixative. The DRG tissue from the cervical up to the lumbar vertebrae was isolated and processed using standard histochemical tissue processing techniques for light and electron microscopy [8]. Multiple slides were prepared for light & electron microscopy using each DRG tissue. All tissue specimens were subjected to Haematoxylin-Eosin (H&E) and Cresyl violet stains, and a few tissue specimens out of the overall were treated with Toluidine blue stain to study detailed nuclear characteristics. Slides were examined under the light microscope and ultra-high-resolution transmission electron microscope [Model: Phillips EM-410LS, Holland]. Photomicrographs of slides were recorded and further studied.

## 3. RESULTS

### 3.1 Control Group

The Histomorphologic structure of DRG in control group rodents showed normal histologic features

such as light to medium purple-stained large nerve cell bodies surrounded by dark purple-stained small satellite or glial cells (Fig. 1-A), while nerve fibers (axon and dendrites) were stained pink to red. The Schwann cell with dark red cytoplasm and purple nuclei were found around axons indicating myelinated nerve fibers (Fig. 2-A,B). Groups of pseudo unipolar neuronal cell bodies separated by bundles of myelinated nerve fibers with cell bodies possessing large euchromatic nucleus and centrally placed prominent nucleolus was a constant and normally expected feature observed among this group (Fig. 1-A). Electron microscopy revealed pseudo unipolar neurons comprising large cell bodies with predominantly centrally placed large euchromatic nucleus showing distinct nucleolus and perikaryon filled with cell organelles (Fig. 3-A). Satellite cells under electron microscopy appeared very much smaller than neuronal cell bodies and were found to be forming a capsule around neuronal cells, such satellite cells were filled with less perikaryal organelles while nuclei had very little chromatin (Fig. 3-B).

### 3.2 T80 Group

The Histomorphologic structure of DRG in T80 group rodents showed minimal histologic

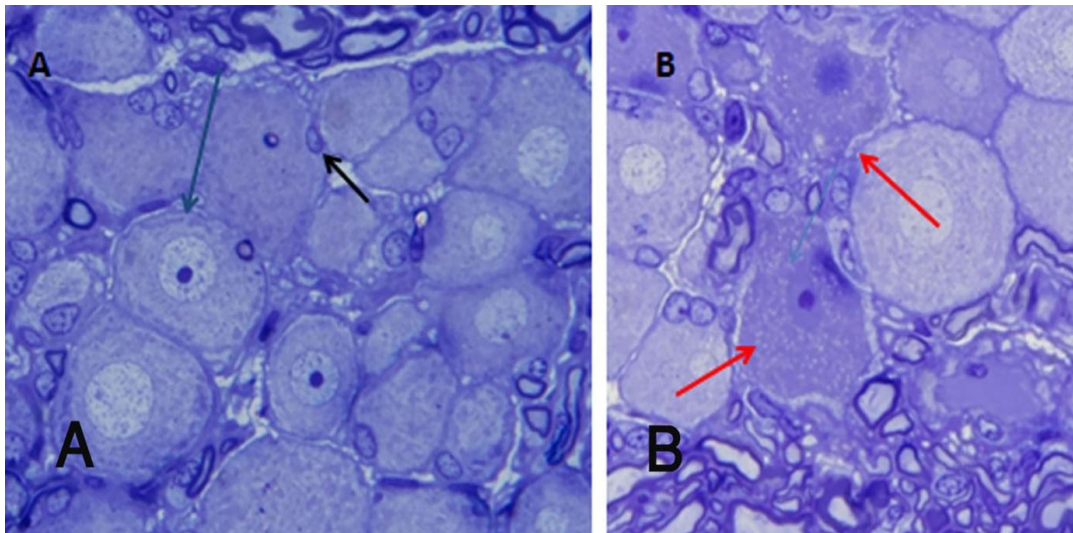
changes in comparison to the control group, such as slightly smaller cells with condensed cytoplasm, the nucleus was found to be heterochromatin with loss of nucleolus (Fig. 4-A,B).

### 3.3 T120 Group

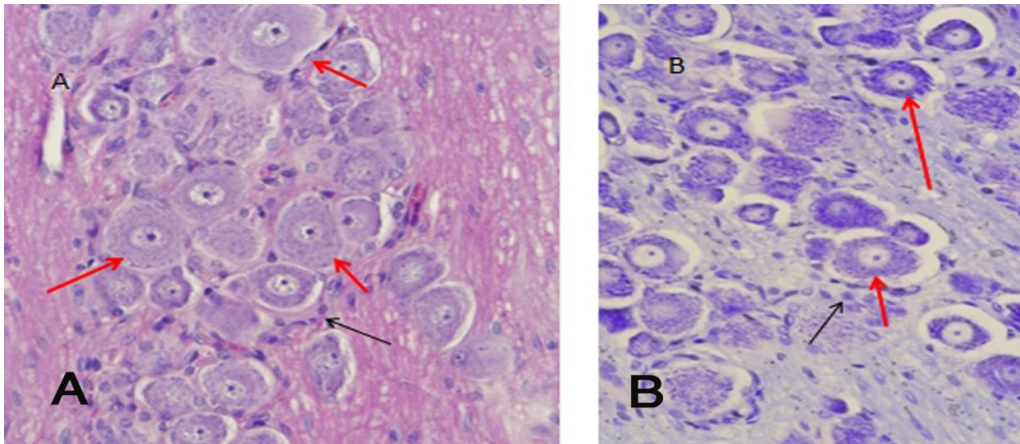
Unlike the control and T80 groups, the T120 group revealed considerable changes in the histomorphologic structure of DRG such as much smaller and darker nerve cell bodies with highly condensed cytoplasm and differentiation of nucleolus in the nucleus was not possible (Fig. 5-A,B).

### 3.4 T160 Group


Extensive histomorphologic changes in the structure of DRG was observed in this group. The series of changes included dark stained small neuronal cell bodies, high cytoplasmic condensation, irregular cell margins, undifferentiable nucleolus, while intermittent neuropils depicted rarefaction (Fig 1-B). Electron microscopy revealed minimal intercellular space between neuronal cell bodies and nuclear heterochromatin (Fig. 6-A) and cross-section showed darkly stained thick bundles of nerve fibers with few normal Schwann cells (Fig. 6-B).



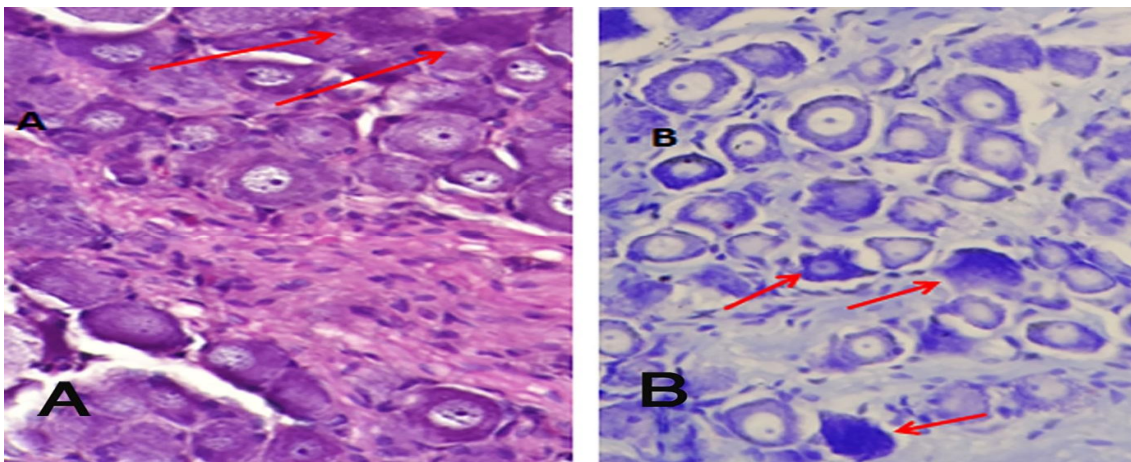
**Fig. 1. Representative Photomicrograph of dorsal root ganglion. (A) control group rat showing normal pseudo unipolar neuronal cell bodies, large euchromatic nucleus and prominent centrally placed nucleolus (Blue arrow) with many small-sized darkly stained satellite cells (Black arrow) surrounding neuronal cell bodies. Neuronal groups are separated by bundles of myelinated nerve fibers. (B) E-160 group rat showing shrunken neuronal cell bodies (Red arrow), unclear cell margins, condensed nuclear material containing ambiguous nucleolus. (Semithin resin sections, Toluidine stain, X1000)**



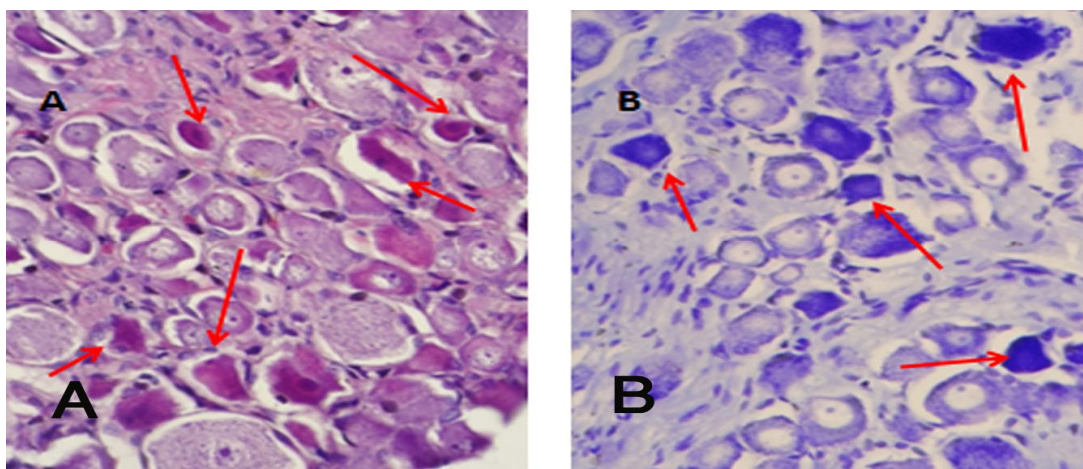
**Fig. 2. Representative Photomicrographs of dorsal root ganglion from control group rats. Distinct nucleus surrounded by cytoplasm can be appreciated. Large normal-looking ganglionic cells (red arrows) surrounded by small satellite cells (black arrows). (A - H&E stain, B - Cresyl violet stain, X400)**



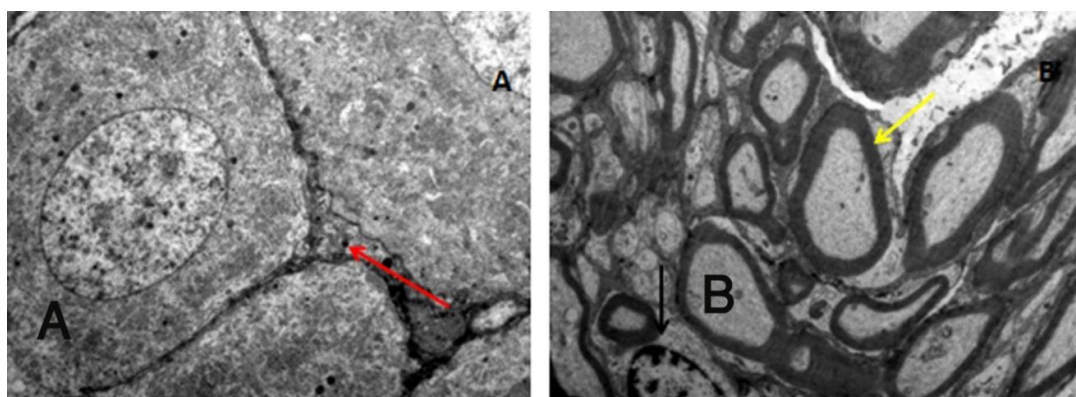
**Fig. 3. Sample electron photomicrographs of dorsal root ganglion of control group rats. (A) single large neuronal cell body (red arrow) with centrally placed large euchromatic nucleus containing distinct nucleolus and perikaryon filled with organelles. (B) Schwann cell (black arrow) near myelinated nerve fibers, satellite cell (blue arrow)**



**Fig. 4. Representative Photomicrographs of dorsal root ganglion from E-80 group rats. Few cells are slightly smaller with condensed cytoplasm (red arrows). (A-H&E stain, B- Cresyl violet stain, X400)**



**Fig. 5. Representative photomicrographs from E-120 group rats. Darkly stained small neuronal cell bodies with indistinct edges, condensed heterochromatic nucleus (red arrow) and normal neurons (without an arrow) are seen. (A-H&E stain, B- Cresyl violet stain, X400)**



**Fig. 6. Sample electron photomicrographs of dorsal root ganglion of E-160 group rats. (A) three neuronal cell bodies with minimal intercellular space (red arrow). (B) dark thick bundles of myelinated nerve fibers (yellow arrow) with part of a Schwann cell (black arrow)**

#### 4. DISCUSSION

The brain is a functionally precise and prompt neuronal organ with excellent efficiency in picking up even the smallest sensory input, hence we took caution not to overly upset the brain by sound and vibration of mobile phones during this experiment. It should be viewed that whatever changes been brought about in the histomorphologic structure of the rodent DRG is by the effect of RF-EMR as there was no other known physical or environmental triggering factor involved. Control group rats showed the normal microscopic structure of DRG. RF-EMR exposed rats of the T80 group depicted minimal cellular changes in DRG, while T120 and T160 groups revealed higher and extensive changes in the

microscopic structure of DRG respectively. The above-observed increase in abnormal histologic changes of DRG was related to the increasing dosage of RF-EMR, clearly indicating the ability of electromagnetic radiation to bring about extra and intracellular modifications in the nervous tissue. Reduction in neuronal cell size with the condensation of cytoplasm, reduction of nuclear size, nuclear condensation, and non-differentiable nucleolus suggestive of heterochromatin and varying degree of demyelination were our experimental findings that accounted for the highly significant damaging effect of RF-EMR on DRG.

Highly significant damage to the nervous tissue has been reported on exposure to mobile phone

radiation [9]. Reduction in cell size can cause a reduction in functionality by affecting cell size-dependent metabolism leading to disorders and aging [10]. Change in the nuclear structure causing heterochromatin formation indicates changes in DNA [11]. A study on Chinese hamster cells showed structural DNA changes on exposure to microwaves radiation [12]. Another study on rats revealed changes in the DNA sequence of testicular and neuronal cells on long term exposure to microwaves of 2.5Ghz [13]. Breakage of DNA was noted in rat nerve cells on exposure to RF-EMR [14]. All this evidence is suggestive of cellular changes at the DNA level that can occur in nervous tissue on excessive and prolonged exposure to RF-EMR. Such cellular changes along with demyelination might lead to neuronal degenerative disorders or even cancerous conditions. Limitations of our study include lack of long-term exposure and genetic study of the DNA which would further provide information regarding the extent of genetic modification and might shed more light on the disease, disorder, and aging process.

## 5. CONCLUSION

Our study revealed that the Dorsal root ganglion of Albino rats exposed to different doses of Radiofrequency electromagnetic radiations from mobile phones exhibited extracellular as well as intracellular changes. Such changes were not observed in the control group rats. The severity of changes in the cell was dose-dependent. Further studies are required to demonstrate in-depth genetic and epigenetic alterations on long term exposure to RF-EMR.

## 6. RECOMMENDATIONS

We recommend to conduct similar researches in various weather based temperatures and different parts of central nervous system.

## CONSENT

It is not applicable.

## ETHICAL APPROVAL

This study was conducted after due ethical approval by the institutional animal ethics committee, Central animal house, (401/RO/C/2001/CPCSEA).

## DECLARATION

The manuscript has been read and approved by all the authors, the requirements for authorship

have been met and that each author believes that the manuscript represents honest work.

## COMPETING INTERESTS

Authors have declared that no competing interests exist.

## REFERENCES

1. Sánchez E. What effects do mobile phones have on people's health. Copenhagen, WHO Regional Office for Europe; 2006. [Internet] Available:<https://www.euro.who.int/document/e89486.pdf>
2. Sanou B. ICT Facts & Figures. The world in ItU. 2015;150. [Internet] Available:<https://www.itu.int/en/ITU-D/Statistics/Documents/facts/ICTFactsFigures2015.pdf>
3. Boice Jr JD, Tarone RE. Cell phones, cancer, and children. *J Natl Cancer Inst.* 2011;103(16):1211–3. [Internet] Available:<https://doi.org/10.1093/jnci/djr285>
4. Nascimento RS, Santiago MF, Marques SA, Allodi S, Martinez AMB. Diversity among satellite glial cells in dorsal root ganglia of the rat. *Brazilian J Med Biol Res.* 2008;41(11):1011–7. [Internet] Available:[https://www.bjournal.org/wp-content/uploads/articles\\_xml/1414-431X-bjmr-S0100-879X2008001100011/1414-431X-bjmr-S0100-879X2008001100011.x72422.pdf](https://www.bjournal.org/wp-content/uploads/articles_xml/1414-431X-bjmr-S0100-879X2008001100011/1414-431X-bjmr-S0100-879X2008001100011.x72422.pdf)
5. Teimori F, Khaki AA, Rajabzadeh A, Roshangar L. The effects of 30 mT electromagnetic fields on hippocampus cells of rats. *Surg Neurol Int.* 2016;7:70. [Internet] Available:<http://surgicalneurologyint.com/wp-content/uploads/2016/07/6791/SNI-7-70.pdf>
6. Taufiq F, Shariff EA, Ahmad A. Effect of radiofrequency electromagnetic radiation on the spinal cord of albino rats: A neurohistological study. *Saudi J Med.* 2018;3(11):620–8. [Internet] Available:<http://scholarsmepub.com/wp-content/uploads/2018/12/SJM-311-620-628-final.pdf>
7. Taufiq F, Srivastava M. Effects of Radio-Frequency Electromagnetic Radiations (RF-EMR) on Cerebellar Cortex of Albino Rats: - A Light and Electron Microscopic Study. *Saudi J Med.* 2018;3(3):86–94. [Internet]

- Available:<http://scholarsmepub.com/wp-content/uploads/2018/03/SJM-33-86-94-c.pdf>
8. Adjene JO, Ajakaye IO, Nosakhare PO. Morphological effects of chronic efavirenz administration on the kidney of adult Wistar rats. *Genomic Med Biomarkers, Heal Sci.* 2011;3(2):76–80. [Internet]. Available:<https://reader.elsevier.com/reader/sd/pii/S2211425411000057?token=3833DC9822FC253030CE43F9467FEF188C5A92ADB43EC6438AB087D67C0992AF13730EF6FE46C65F583D7FE0F222AAC5>
  9. Salford LG, Brun AE, Eberhardt JL, Malmgren L, Persson BRR. Nerve cell damage in mammalian brain after exposure to microwaves from GSM mobile phones. *Environ Health Perspect.* 2003; 111(7):881–3. [Internet] Available:<https://ehp.niehs.nih.gov/doi/pdf/10.1289/ehp.6039>
  10. Miettinen TP, Björklund M. Mitochondrial function and cell size: an allometric relationship. *Trends Cell Biol.* 2017;27(6): 393–402.
  11. Dahl KN, Ribeiro AJS, Lammerding J. Nuclear shape, mechanics, and mechanotransduction. *Circ Res.* 2008; 102(11):1307–18. [Internet] Available:<https://www.ahajournals.org/doi/epub/10.1161/CIRCRESAHA.108.173989>
  12. Garaj-Vrhovac V, Horvat D, Koren Z. The effect of microwave radiation on the cell genome. *Mutat Res Lett.* 1990;243(2): 87–93.
  13. Sarkar S, Ali S, Behari J. Effect of low power microwave on the mouse genome: a direct DNA analysis. *Mutat Res Toxicol.* 1994;320(1–2):141–7.
  14. LAI H. Single-and double-strand DNA breaks in rat brain cells after acute exposure to radiofrequency electromagnetic radiation. *Int J Radiat Biol.* 1996;69(4):513–21.[Internet]. DOI:<https://doi.org/10.1080/095530096145814>

© 2021 Taufiq et al.; This is an Open Access article distributed under the terms of the Creative Commons Attribution License (<http://creativecommons.org/licenses/by/4.0>), which permits unrestricted use, distribution, and reproduction in any medium, provided the original work is properly cited.

*Peer-review history:*  
*The peer review history for this paper can be accessed here:*  
<http://www.sdiarticle4.com/review-history/66168>