

Histological Changes to the Rat Mandibular Condyle in Response to Long-term Exposure to an Extremely Low Frequency Magnetic Field

Ibrahim H Tacir^{1*}, Sabiha Z Ulku¹, Muzaffer A Ketani², Mehmet Z Akdag³

1. Department of Prosthetic Dentistry, Faculty of Dentistry, Dicle University, Diyarbakır 21280, Turkey

2. Department of Histology, Medical Veterinary Faculty, Dicle University, Diyarbakır 21280, Turkey

3. Department of Biophysics, Medical Faculty, Dicle University, Diyarbakır 21280, Turkey

*E-mail: ihtcr@hotmail.com

Abstract

Background: The need for electrical power continues to increase along with the rapidly growing economies of industrialized countries. However, the effects of electrical fields (EFs) on human health remain unclear. Hence, the aim of the present study is to evaluate the histological effects of an extremely low frequency magnetic field (ELF-MF) on the rat mandibular condyle. **Methods:** Twenty female Sprague–Dawley rats were randomly allocated to one of two groups (n = 10): an untreated control group and an ELF-MF group exposed to a 1.5-mT ELF-MF for 4 h per day for 6 months. After exposure, the left mandibular condyles of all rats were collected for histopathological examinations. **Results:** The histopathological changes to the ELF-MF group included a non-homogenous appearance and decreased thickness of the hypertrophic layer, irregular appearances of bone marrow cavities, significant deterioration, and delayed calcification and ossification. There were no significant differences in the thicknesses or histomorphometric appearances of the fibrotic, proliferative, and hypertrophic layers of the mandibular condyle of rats between the groups ($p = 0.05$). **Conclusion:** Long-term ELF-MF exposure can induce histopathological changes to the mandibular condyle of rats.

Keywords: bone; extremely low frequency magnetic field (ELF-MF); mandibular condyle; rats

Introduction

The skeleton provides structural support to the entire body.¹ Many normal and abnormal processes cause changes to the maxillary and mandibular bone tissue.² The prevention of bone loss due to aging, menopause (hormonal changes), immobilization, and harmful external stimuli, such as a magnetic field (MF), normally requires understanding of the factors that regulate restructuring activities.³

Physical stimuli, especially mechanical loading, are the most important determinants of bone mass and architecture.⁴ The biological effects of MF on osteoporosis in both humans and experimental animal models are known. However, there are no data in the literature regarding the histological and histomorphometric changes to the condyle in response to an extremely low frequency (ELF) MF.

Long-term exposure to an ELF-MF or radio frequency has been associated with an increased risk of adverse health outcomes, which is the main problem in relevant research.^{5,6} Therefore, the aim of the present study is to determine whether long-term ELF-MF exposure causes

structural changes in bones using the mandibular condyle of rats as samples.

Methods

The study protocol was approved by the Ethics Committee of Dicle University (Diyarbakır, Turkey) and conducted in accordance with the principles of the use of animals for scientific research. A total of 20 female Sprague–Dawley rats weighing 157–226 g were housed in an animal care facility under a 14:10-h light:dark cycle at a constant temperature of 22 °C ± 3 °C and humidity of 45% ± 10% with free access to water and standard rat pellets throughout the experimental period. After acclimation, the rats were randomly assigned to one of two groups (n = 10): the control group (CNT) or the ELF-MF Group (ELF-MF). All rats in the ELF-MF group were exposed to 1.5 mT of ELF-MF for 4 h per day for 6 months.

The MF was produced using Helmholtz coils in a Faraday cage. The magnet was constructed by wrapping 125 turns of insulated soft copper wire with a diameter of 1.5 mm. An electrical current of 1.5 mT was generated using an AC power supply (Adakom, Turkey)

and passed through the Helmholtz coils (Figure 1). MF intensities were measured once per week at 15 different points on the methacrylate cages using a Bell 7030 Gauss/Tesla meter (FW Bell, Inc., Orlando, FL, USA) to ensure homogeneity in the field during the experiment. The animals in the ELF-MF group were exposed to a 1.5-mT ELF-MF for 4 h per day in methacrylate cages for 6 months. The rats in the control group were not exposed to an EF and were merely housed with free movement in identical methacrylate cages.

All rats were euthanized by intramuscular injection of 100 mg of ketamine/kg body weight, and the left mandibular condyle was collected, fixed in 10% neutral formalin, and decalcified in 5% formic acid. For histopathological evaluations, 5 μ m-thick sections of paraffin-embedded mandibular condyle specimens were stained with hematoxylin and eosin, followed by trichrome stain. Histological evaluations were performed using an Eclipse 400 light microscope (Nikon Corporation, Tokyo, Japan) at an objective magnification of $\times 10$. The thickness of the capillary layer was measured using an ocular micrometer. Measurements were made at the middle of the mandibular condyle. Histological staining of the three layers of each joint region [i.e., fibrous (joint), proliferative (chondrogenic), and maturative/hypertrophic] was scored for comparative analysis

All statistical analyses were performed using SPSS version 15 software (SPSS, Inc., Chicago, IL, USA). Differences in the thicknesses (μ m) of mandibular condyle layers between groups were identified using the Kruskal–Wallis test. A probability (p) value of 0.05 was considered statistically significant.



Figure 1. Experimental set-up

Results

The regular fibrotic layer and open fibroblastic activity were observed in the fibrotic area of the mandibular condyle of rats in both groups. The proliferative layer of the control group was regular, with an open passage from the proliferative layer to the hypertrophic layer (Figure 2). However, the cell diameter of the hypertrophic layer was significantly greater in the control group. In the ELF-MF group, a non-homogenous appearance and a decrease in layer thickness were observed in the hypertrophic layer. Bone marrow cavities were normal in the control group, but irregular in the ELF-MF group. In addition, an increase in bone marrow was observed in the ELF-MF group (Figure 3). Regular transition from the hypertrophic area to the ossification layer was observed in the control group, and significant deterioration and delayed calcification and ossification were observed in the ELF-MF group. Histomorphometric analysis showed no significant difference in the thicknesses of the fibrotic, proliferative, and hypertrophic layers of the mandibular condyles of rats between groups (Figures 4 and 5).

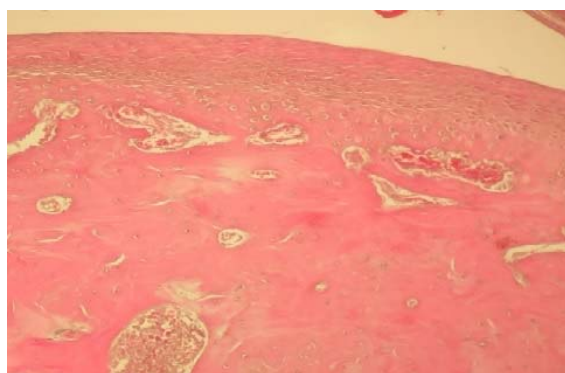


Figure 2. The histologic appearance of the control group (HE stain, $\times 10$)

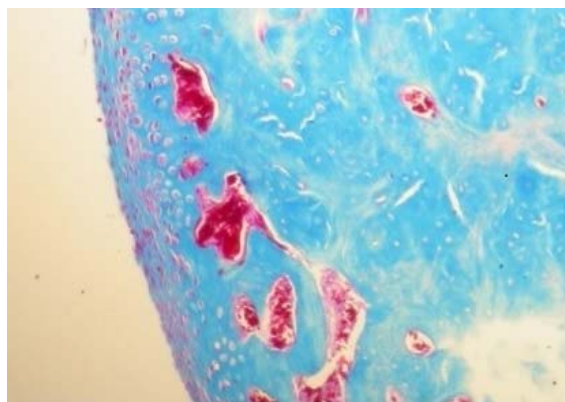


Figure 3. The histological appearance of the ELF-MF group (HE stain, $\times 10$)

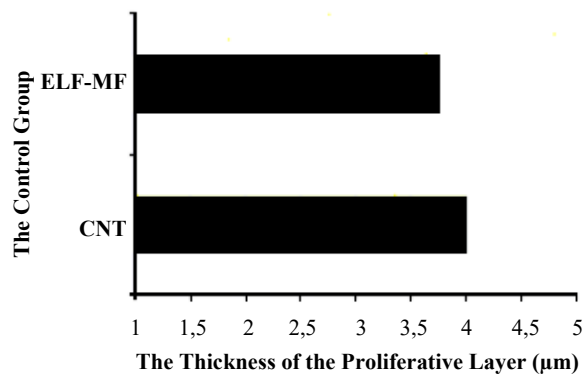


Figure 4. The Thickness of the proliferative layer (µm). There was no significant difference in proliferative layer thickness between groups

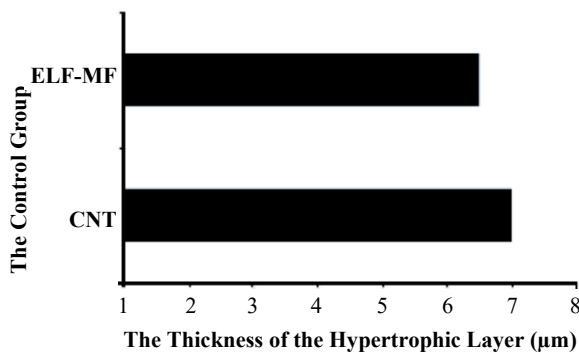


Figure 5. The thickness of the hypertrophic layer (µm). There was no significant difference in hypertrophic layer thickness between groups.

Discussion

Recently, the number of studies on the biological effects of MFs has increased because of the increased use of electronic technologies, high-voltage power transmission, and magnetic resonance imaging methods.^{7,8} Some studies have reported that an MF may affect the behavior of osteoblast-like cells, stimulate the early stages of osteoblast maturation in culture, accelerate the cellular proliferation of osteoblasts, and stimulate an increase in total bone mineral content.^{9,10}

Previous studies provided no clear biological implications of MFs on human health. Several studies have shown positive effects of MFs on bone fractures, osteoporosis, and pseudoarthrosis.¹¹ Some authors are convinced that EFs have an impact on the healing of bones, tissue repair, and other body functions.^{12,13} However, the majority of studies failed to explain the effects of ELF-MFs on human health. Meanwhile, other studies have shown that an ELF-MF can activate bone formation and

development, inhibit osteoclastic activity, contribute to the healing process of bone fractures, and promote granulation and the formation of fibrous tissue in wound healing. Although some studies have concluded that an ELF-MF poses no risk to human health, others have reported deleterious effects on the immune system, the induction of carcinogenic effects, such as leukemia, and the formation of neurologic diseases, endocrine system disorders, degenerative heart diseases, vascular damage, and emphysema. The effects of ELF-MF on the mandibular condyle of normal rats have not been fully assessed. Hence, the aim of the present study was to investigate the effects of ELF-MF on the histological and histomorphometric structures of the mandibular condyles of rats.

Previous study⁵, investigated the possible effects of an ELF-MF on the geometric and biomechanical properties of the bones in a rat model and found a significant decrease in the cross-sectional area of the femoral shaft of rats exposed to a 100-µT MF, as compared to the sham-treatment group and rats exposed to a 500-µT MF. The maximum load was increased in rats exposed to MFs of 100 and 500 µT as compared to that of the sham rats. The cortical thicknesses of the femurs of MF-exposed rats (100 and 500 µT) were significantly decreased as compared to those of rats in the sham-treatment group.¹⁴ In the present study, the diameters of cells in the hypertrophic layers of rats in the ELF-MF group were significantly increased along with irregularities of the bone marrow and increased calcification and ossification.

Conclusions

Long-term exposure to an ELF-MF can cause histopathological changes in the mandibular condyle structure of rats. However, these findings should be supported by hormonal, epidemiological, and mineral density studies.

Funding

None

Conflict of Interest Statement

The authors have no conflict of interest to report in regards to this study.

Received: December 8, 2018 Accepted: March 12, 2019

References

1. Perilli E, Briggs AM, Kantor S, Codrington J, Wark JD, Parkinson IH, et al. Failure strength of human vertebrae: prediction using bone mineral density measured by DXA and bone volume by micro-CT. *Bone*. 2012;50:1416-25.

2. Lindhe I, Bressan E, Cecchinato D, Corra E, Toia M, Liljenber B. Bone tissue in different parts of the edentulous maxilla and mandible. *Clin Oral Impl Res.* 2012;24:372-77.
3. Clarke BL, Khosla S. Physiology of bone loss. *Radiol Clin North Am.* 2010; 48: 483-95.
4. Hart NH, Nimphius S, Rantalainen T, Ireland A, Sifarikas A, Newton RU. Mechanical basis of bone strength: influence of bone material, bone structure and muscle action. *J Musculoskelet Neuronal Interact.* 2017;17: 114-39.
5. Akdag MZ, Dasdag S, Ketani MA, Sagsoz H. Effect of extremely low frequency magnetic fields in safety standards on structure of acidophilic and basophilic cells in anterior pituitary gland of rats: an experimental study. *J Int Dent Med Res.* 2009;2:61-6.
6. Karadede B, Akdag MZ, Kanay Z, Bozbiyik A. The effect of 900 MHz Radiofrequency (RF) radiation on some hormonal and biochemical parameters in rabbits. *J Int Dent Med Res.* 2009;2:110-5.
7. Binhi AN, Prato FS. Biological effects of the hypomagnetic field: an analytical review of experiments and theories. *PLoS One.* 2017;12:e0179340.
8. Geng D, Xu G, Zhang X, Xing L, Guo H, Yan W, et al. Effects of electromagnetic field of UHF transmission lines exposure on testis tissue in mice. *IEEE Trans Magn.* 2009;45:4853-6.
9. Chang WHS, Chen LT, Sun JS, Lin FH. Effect of pulse-burst electromagnetic field stimulation on osteoblast cell activities. *Bioelectromagnetics.* 2004;25:457-65.
10. Kunt H, Senturk I, Gonul Y, Kokmaz M, Ahsen A, Hazman O, et al. Effects of electromagnetic radiation exposure on bone mineral density, thyroid, and oxidative stress index in electrical workers. *Onco Targets Ther.* 2016;9:745-54.
11. Takano-Yamamoto T, Kawakami M, Sakuda M. Effect of a pulsing electromagnetic field on demineralized bone-matrix-induced bone formation in a bony defect in the premaxilla of rats. *J Dent Res.* 1992;71:1920-5.
12. En-tong W, Min Z. Regulation of tissue repair and regeneration by electric fields. *Chin J Traumatol.* 2010;13(1):55-61.
13. Hong ME, Yoon KH, Jung YY, Lee TJ, Park S, Sohn UD, et al. Influence of exposure to extremely low frequency magnetic field on neuroendocrine cells and hormones in stomach of rats. *Korean J Physiol Pharmacol.* 2011;15(3):137-42.
14. Akdag MZ, Dasdag S, Erdal N, Buyukbayram H, Gurgul S. The Effect of Long-Term Extremely Low-Frequency Magnetic Field on Geometric and Biomechanical Properties of Rats' Bone. *Electromagn Biol Med.* 2010;29:1-12.